

Ceramic implants: an alternative or a primary choice?

Clinical aspects and operating procedures

Dr Riccardo Scaringi, Dario Viera & Dr Michele Nannelli, Italy

Introduction

Today, grade 2 titanium is considered the standard material for prosthetic implant rehabilitation in all situations that may arise in the dental field. The excellent bone integration, good tissue biocompatibility, resistance to corrosion and biomechanical stress mean that titanium implants are an optimal clinical solution, including with regard to the standardisation of surgical protocols that have made it possible to obtain solutions with an acceptable result even in the hands of less experienced practitioners.¹ In light of this, one might wonder: what is the reason for using zirconia implants and in what circumstances could they be a primary choice compared to titanium implants? Since the introduction of titanium replacement materials, there has been an evolution in ceramic materials, culminating in zirconia, due to its mechanical properties associated with the characteristic biological responses resulting in high biocompatibility and low affinity to bacterial plaque. Zirconia also offers excellent tissue mimesis thanks to its whitish colour that simulates the colour of teeth.²

In 1969, Sandhaus was the first to make aluminum oxide (AL₂O₃) implants;³ in 1974, the Tubingen implant, made of polycrystalline alpha-alumina, was introduced and clinically tested.⁴ Despite the excellent bone integration results, there was the drawback of implant fracture due to factors related to the mechanical properties of alumina itself, as it has low bending strength. This problem is largely resolved with the use of zirconia, a material which replaces the values of titanium⁵ Long-term success not only requires osseointegration but, above all, an excellent response to soft tissue by creating a mucous barrier around the implants in order to develop a kind of seal between the marginal bone and oral cavity. It is well-known that, after implant insertion, the formation of soft tissue around the implant collar is characterised by the gradual transition from a clot to granulation tissue and consequently the formation of an epithelial barrier that turns into the maturation of connective tissue.⁶ Any gaps that may remain between the implant and connective tissue could promote bacterial growth. The epithelial barrier contains

Langerhans cells and local immune defence cells.⁷ The peri-implant epithelium adheres to the implant through hemidesmosomes and internal basal lamina of the lower region of the interface between epithelium and implant, with poor adhesion to the titanium surface.⁸ The rapid epithelial growth at the expense of the connective tissue generates gaps where the seal is not guaranteed, with consequent bacterial colonisation. In addition, if epithelial growth were to occur along the implant axis during healing, osseointegration would not be adequate, resulting in consequent bone resorption.⁹

Additional studies were conducted to determine appropriate surface treatment with regard to implant shape and the possibility of having one-piece or two-piece implants that could obtain comparable data to that obtained for titanium implants.¹⁰ The demand for aesthetics in the anterior regions of single and multiple restorations highlights the disadvantage of having submucosal areas with greyish shades that emphasise the need to combine zirconia abutments and crowns, allowing greater translucency compared to titanium with metal-ceramic.^{11,12} The low adhesion of oral cavity bacteria to ceramic surfaces makes their use beneficial, also enhancing the use of zirconia coronal insert implants.¹³ Yttria-stabilisation of tetragonal zirconia polycrystal (Y-TZP) has made it possible to obtain an endosseous implant able to withstand breaking loads sometimes higher than Titanium.¹⁴ One-piece implants were the first to be introduced in clinical practice because of their optimal biological and functional integration and, despite the prosthetic limitations, they are still recommended in implant sections reduced to less than 4.0mm. Their prosthetic peculiarity means that they are suitable for partial edentulism, even in aesthetic frontal regions and thin biotypes, and in areas where the masticatory load is at its maximum. The strong prosthetic limitation is an important element, especially in cases of interconnection where the disparallelism could generate difficulties in the construction of the primary structure. In fact, the abutments, which are usually represented by a conoid-like geometry or similar, are difficult to treat with diamond drills in the oral cavity because the polycrystalline structure could undergo stress due to modification of

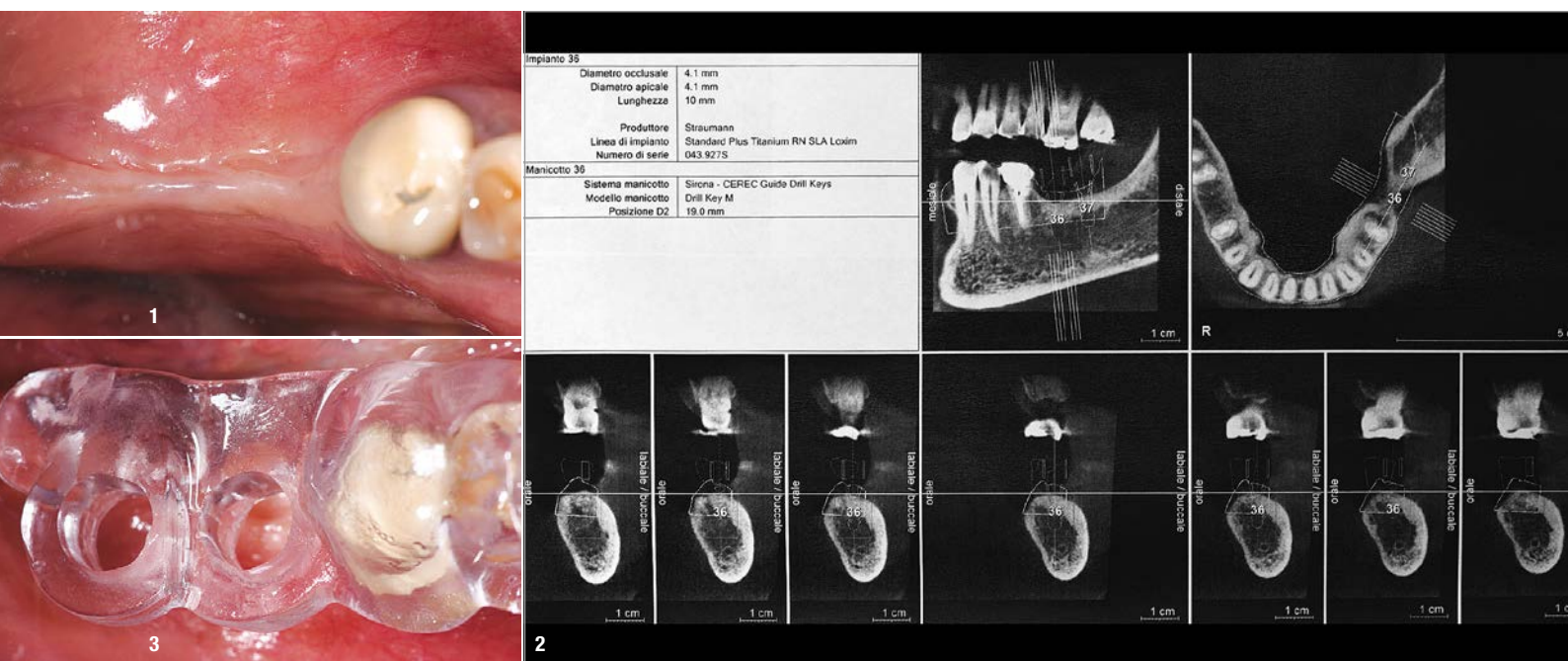


Fig. 1: Pre-surgical situation, shows the lack of connective tissue and residual bone atrophy. To be taken into account when comparing the result obtained after completion of the implant restoration. **Fig. 2:** Representative axial sections of CBCT at sites of surgical interest. **Fig. 3:** Positioning of the surgical template for correct implant placement in the transverse space and axial direction.

the internal lattice, leading to the fracture of the implant itself. In addition, the presence of an abutment limits the regenerative potential of the site and forces the abutment to become exposed, with inevitable immediate, and even indirect, load caused by the movement of the tongue and related to chewing and functional cycles.¹⁵

The presence of two-piece zirconia implants represent an evolution compared to one-piece implants, providing the possibility to customise a dedicated abutment or to choose among a range of abutments, which, although limited, provides the clinician with a prosthetic variable which is able to optimise the prosthesis according to aesthetics and biomechanics. We are fully aware of all the limitations of implant geometries in titanium implants but, above all, we know that the micro-gap generated between implant and abutment leads to a bacterial build-up that causes the soft and hard tissue to suffer.^{16,17} This has led some authors to restudy the behaviour of the respective implants, without making substantial notes on the differences between titanium and zirconia implants for both prosthetic connections.¹⁸⁻²⁰ When analysing two-piece implants, it is important to establish that the abutment can be held within the implant by cementing or screwing. The screw-retained connection is the most common one on the market, can be easily reproduced in the laboratory and can be made of different materials, ranging from titanium to gold, PEEK and carbon-reinforced PEEK. Although not in contact with tissues, in the holistic view, the metal screw does not define the restoration as Total Metal Free. Carbon-reinforced PEEK is a PEEK (Polyether Ether

Ketone) screw reinforced with carbon fibre, having the following characteristics:

- Radiotransparent, i.e. not visible on radiographs;
- Elasticity modulus > 160 GPa;
- Flexural Strength > 1,100 MPa;
- Tensile Strength 2,000 MPa;
- Biocompatible according to ISO 10993.

In terms of intrinsic structure, we find that the carbon fibres have a continuous longitudinal trend at 60% inserted in a 40% PEEK matrix; this promotes adequate stability and high resistance to the stress to which it will be subjected during screwing, in the abutment retention phase and during chewing.

Clinical case

In the case in question, the female patient ASA 1 presented with edentulous molars in the third quadrant. The patient had already undergone implant-prosthetic rehabilitation with the insertion of two titanium implants which, after a short period of function, began to show pain and bleeding according to the patient. Despite maintenance treatment administered both at home and professionally, the clinical situation did not improve and, after a few months, the patient had to remove the entire implant restoration, resulting in circumferential bone resorption at both implants (Fig. 1). One year after the extraction, we decided to re-examine the edentulous area by subjecting the patient to CBCT (Fig. 2). The diagnostic examination showed vertical bone resorption while maintaining an adequate size for the in-

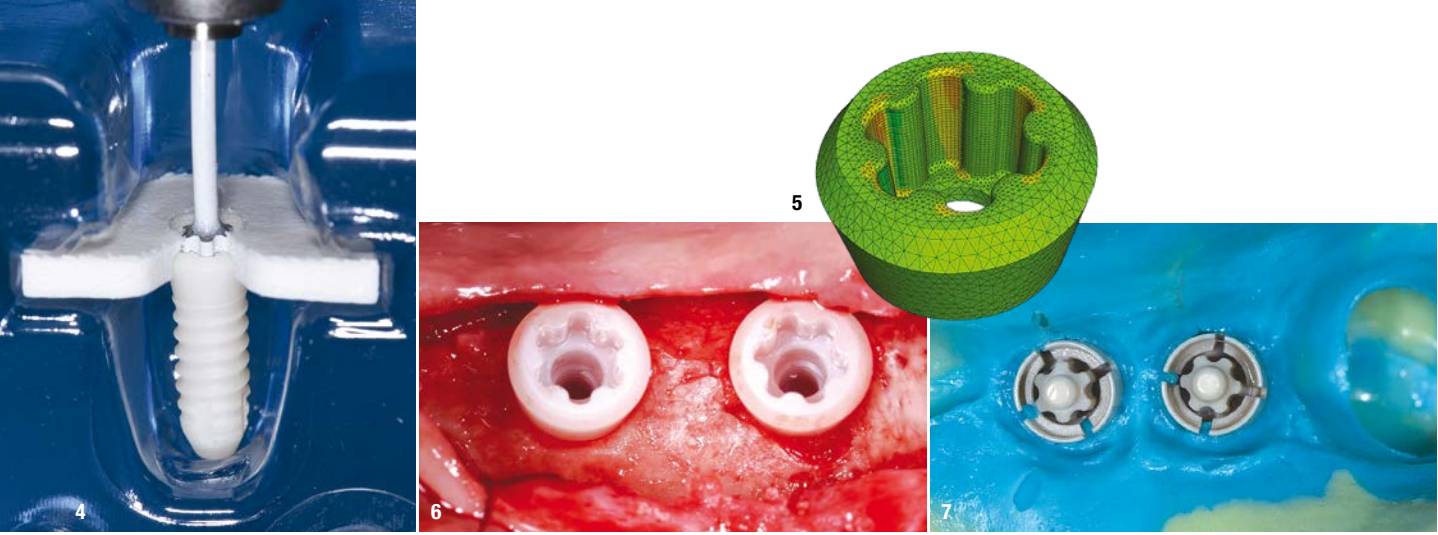


Fig. 4: Selection of the CERALOG zirconia implant (BioHorizons Camlog). The image shows the handpiece mounter in order to control the implant insertion for torque and speed. **Fig. 5:** Detail of the Hexalobe connection and its representation using a mathematical finite element method, showing the reduction of mechanical stress related to zirconia in the connection cavities. **Fig. 6:** The need for the residual connective tissue to be preserved has dictated open flap surgery, even if with less trauma. **Fig. 7:** Impression copings according to the tear-off technique using silicone.

sersion of two 10mm implants and leaving adequate safety space from the mandibular canal. The bone quality proved to be D3 type. In our therapeutic protocol, we prefer a digital approach and, where possible, we prefer to produce a surgical template in order to optimise the position between the implants and the antagonists, with a view to optimising the result (Fig. 3). Given the previous implant failure, we have given the patient an alternative in the choice of materials compared to the previous project, offering the possibility of performing a Total Metal Free (TMF) treatment. Evaluating the choice of implant was aimed at making it possible to use a two-piece zirconia implant due to

the relative vertical dimension present with respect to the antagonists, the abrasion marks on the residual teeth and the relative bone quality. Moreover, during the treatment of a relapse, I believe that any practitioner wants to minimise the risk of another failure. The decision was made to go with a new generation implant with some special features that were suitable for resolving the case.

Materials and methods

The zirconia implant chosen for the patient is produced by moulding, in contrast to other zirconia implants made

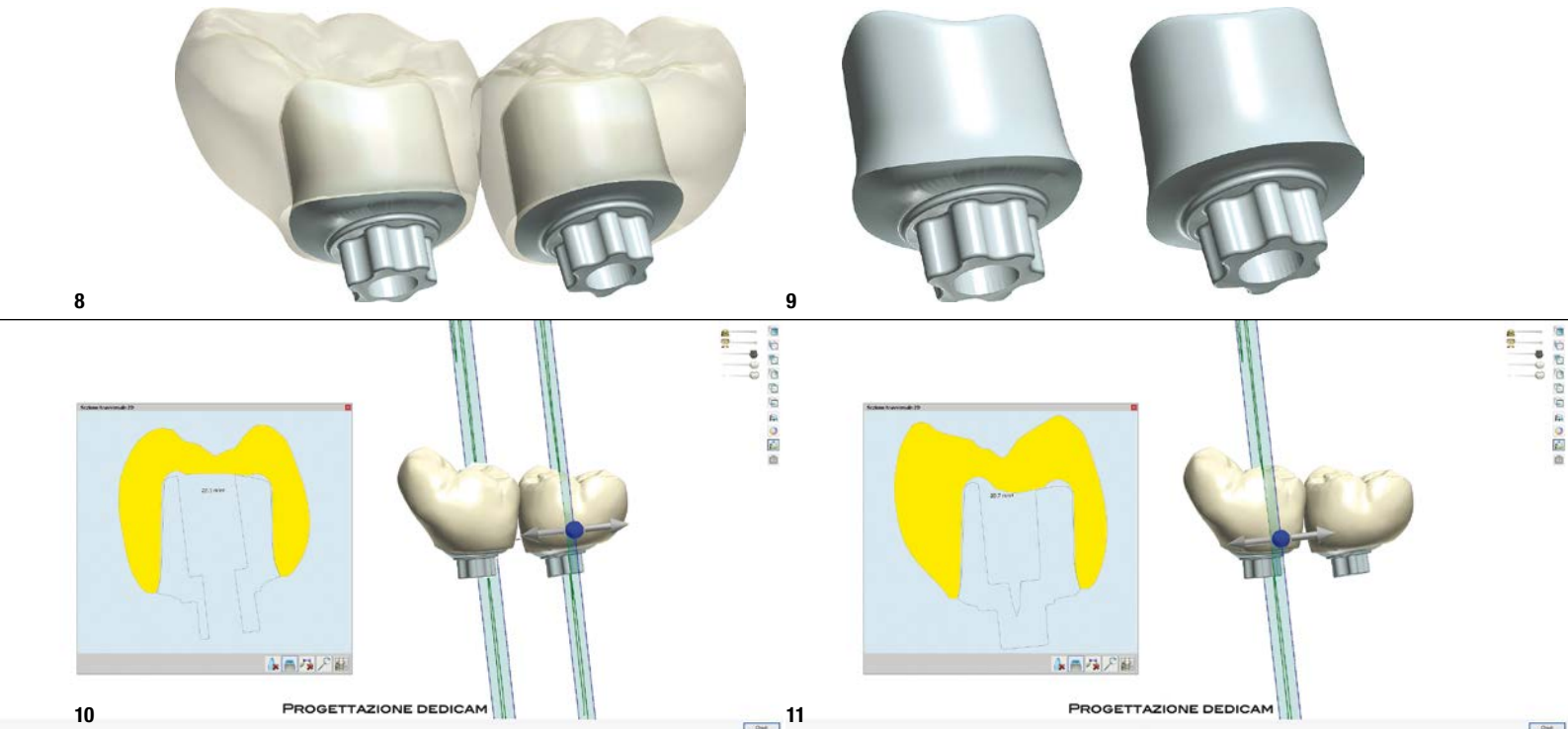
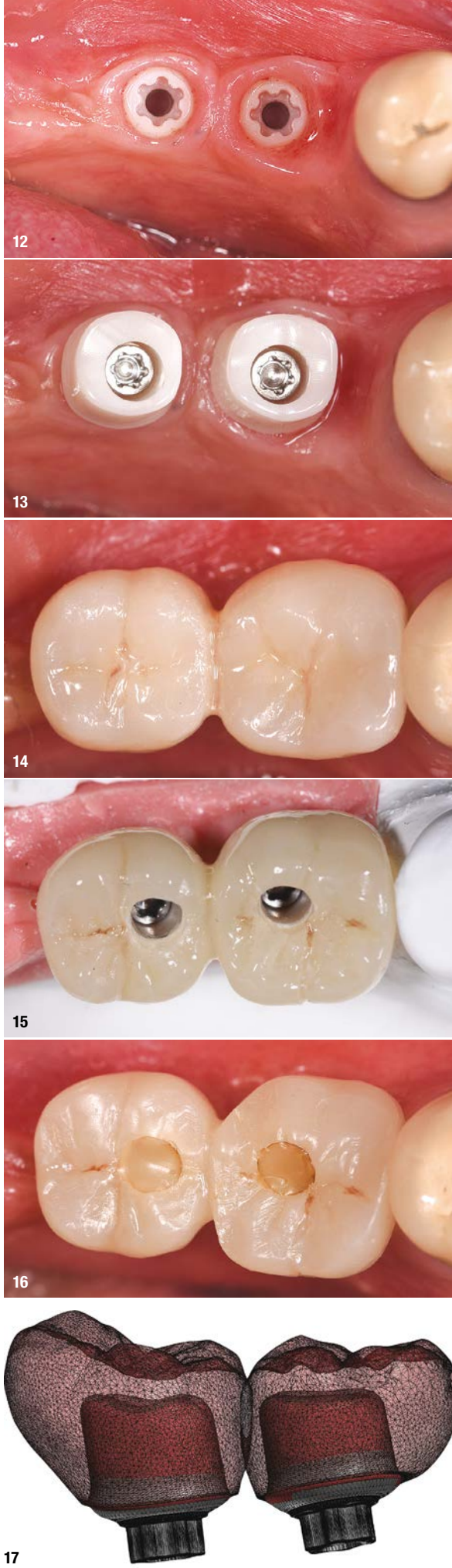


Fig. 8: Same view from another angle that amplifies the view of crowns and abutments. The Dedicam milling centre is able to make products by confirming the abutment connections in accordance with the parent company's protocols. **Fig. 9:** Full view of the abutments; note the framework beyond the connection that highlights the anatomical shape of the abutment base. **Fig. 10:** This detail relates the through-hole to the anatomy of 37, while the image on the left, in addition to a numerical reference value, shows the part of the crown and abutment. **Fig. 11:** Same image, only dedicated to 36, the numerical value shows a larger crown.

Fig. 12: From this image, it is possible to compare the gain of keratinised tissue surrounding the implant collar. You can also see the optimal tissue health which is typical of zirconia implants. **Fig. 13:** The designed and fabricated abutments are placed on the implants and stabilised with a 15Ncm torque. The abutments were supplied with titanium fixation screws. **Fig. 14:** The crowns were housed and cemented using temporary resin cement so as to be able to act over time if necessary. High precision between structures requires special care during the cementation phase because of the thickness that could prevent them from fitting perfectly, resulting in inaccuracies in occlusal contact points and possible residues in the borderline areas of the abutments, which are often in the aesthetic submucosa area. In this case, we prefer to insert refractory threads that are removed after cementation, limiting the inconvenience of residual cement. **Fig. 15:** Fabrication of a screw-retained, bonded provisional restoration. Given the available space, conventional modelling of two molar elements is preferred. **Fig. 16:** Positioning involves screwing in the through screws and sealing the holes with composite. **Fig. 17:** Digitally modelling the crowns also involves making abutments by subtraction, depending on the material that will be used for the final crowns and abutments.

by drilling (CERALOG, BioHorizons Camlog; Fig. 4). Ceramic injection moulding (CIM) results in an implant whose geometrical and surface structure was created in a mould prior to sintering and hot isostatic pressing (HIP). The variable geometry, smooth on the collar and rough in the endosseous area, optimises soft tissue healing and bone integration. The internal corner-less connection (Hexalobe) also promotes abutment passivation within the implant, improving the fixation action of the screw for better torque transmission to a ceramic implant (Fig. 5). Positioning took place according to the assisted guided surgery technique. Although it could be performed following the flapless technique, we preferred to elevate a flap in order to better condition the tissues around the implant collar due to the initial peculiarity of the tissues present and to exaggerate their transformation after healing (Fig. 6). After a healing period of three months, we took the first impression to make a screw-retained provisional restoration held for two months. Only after a new radiographic finding, we made the final structure following a new impression to establish the exact shape of the conditioned tissue. In both cases, the impression was made in a comparable way based on the use of silicone, with a generic tray. To date, the further changes made to the systems have made it possible for this step to be digitised as well, streamlining some procedures (Fig. 7).

After developing the impression, the dental technician digitally acquired data in the laboratory that enabled the underlying elements and abutments to be modelled. The final anatomical design of the crowns is produced by taking the chewing function as a basis, performed by subtracting from the anatomy of the underlying abutments (Figs. 8–11). The material used determines the variability of the thickness present in the residual spaces, emphasising an aesthetic, resistant result. The shape of the



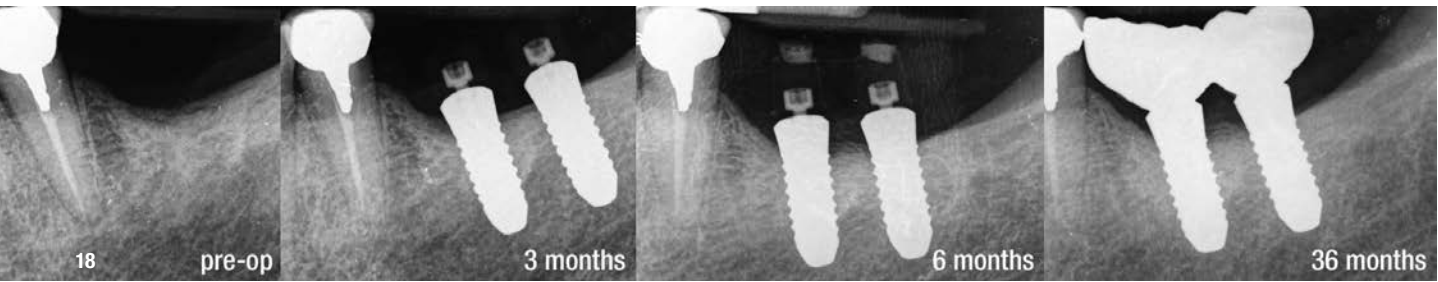


Fig. 18: In addition to CBCT, we always produce intraoral images with a centring machine, so that we can evaluate the changes that will be generated over time; more specifically, follow-up will be 36 months.

Tissue-Level implant allows the collar to be placed in a variable position while maintaining soft tissue stability without affecting the aesthetics of the prosthetic restoration (Fig. 12). Therefore, the entire prosthetic design must take into account the various factors that all contribute to final success (Figs. 13 & 14) and ensure easy long-term maintenance.

Conclusions

We can identify some aspects worthy of particular attention with regard to the use of zirconia implants and, in this specific clinical case, we evaluate them in both the surgical and prosthetic phases. Although worthy of particular attention, some features are typical of implant surgery and it is worth noting that:

- Surgical positioning should be performed using drills in excellent condition, at a low rpm and high torque, paying attention to cooling the surgical site;
- We believe that conditioning with provisionals for a reasonable period can also determine a preload of the implant that allows the implant to heal for a time period which is adequate for the anatomy and a little longer than usual, making it possible to improve bone trabeculation and full cortical maturation (Figs. 15 & 16);
- Analog impression copings are disposable and cannot be hot-sterilised. Their good retention makes it possible to detect correct insertion by engaging the Hexalobe connection (Fig. 7);
- In the phase of the provisional restoration, the screwed technique is undoubtedly the most versatile, making it possible for the provisional restoration to be removed while preserving the soft tissues;
- Today, the digital flow implemented enables a more widespread and versatile use, facilitating communication with the patient and speeding up some practices. Moreover, the clinician can simplify the surgical act using guided surgery;
- Another important element for the final result is making sure that dental technicians are adequately trained in handling such high-performance and technologically-advanced materials, knowing their limits and uses in order to optimise the result with Total Metal Free implantology (Fig. 17).

In this case, the connection of the elements required a change of engagement due to the peculiarity of the implant system. The same change is impractical in the final phase. Perhaps this is a limitation of the system that is still in development for the prosthetic component, aiming for a screwed, bonded solution. The three-year follow-up encourages the implant type to be more widely used, even though it is limited in terms of time and procedure (Fig. 18). In terms of aesthetics, the two-piece zirconia implant is an excellent alternative to conventional implantology with titanium implants. A recommendation to the surgeon is to only use zirconia implants after appropriate clinical training.

Acknowledgements: Thanks to Mr. Dario Viera, dental laboratory owner and dental technician who, with his technical skills and in-depth knowledge of materials, made obtaining the results described in this document possible.



about the author



Dr Riccardo Scaringi is a Professor of specialisation courses in dental implant prosthesis and digital support technologies, at various national universities. He is a frequently invited speaker at national congresses on topics related to surgical prosthetics. He is also an active member at the most prestigious international scientific associations in the field of technological and digital surgery. Scaringi is the author of various scientific publications and texts.

contact

Dr Riccardo Scaringi
 Kiral Dental srl
 Via Lattanzio 23
 20137 Milan, Italy
 Phone: +39 02 551 1620
 info@riccardoscarings.com
 kiraldental.com

